

Review of surgical repair of traumatic iridodialysis

Ass.Proff.Dr.Haider M. Ibrahim : MBChB , FICMS Ophth.*

*College of Medicine/Kufa University

مراجعة التصليح الجراحي لخلع القزحية الرضي

خلع القزحية هو انفصال القزحية من اتصالها للجسم الهدبي . التداخل الجراحي لخلع القزحية يتقرر عندما يكون الانفصال كبيرا ومسببا اعراض . هذه الدراسة شملت احد عشر عينا لأحد عشر مريضا لإصلاح خلع القزحية الرضي جراحيا باستخدام طريقة الحجرة الامامية المفتوحة .

Abstract:

Iridodialysis is a dehiscence of the iris from the ciliary body at its root.

Surgical intervention in iridodialysis is indicated when the tear is large and causing symptoms.

In this study 11 eyes of 11 patients with traumatic iridodialysis were included to repair the iris defect using open chamber technique .

Key Words: Iridodialysis, open chamber technique

Introduction:

Iridodialysis is a dehiscence of the iris from the ciliary body at its root. The pupil is typically (D) shaped and the dialysis is seen as a dark biconvex area near the limbus .An iridodialysis may be asymptomatic , if covered by the upper lid , but if exposed in the palpebral aperture , uniocular diplopia and glare may ensue , sometimes necessitating surgical repair .Traumatic aniridia(360° iridodialysis) is rare .(1)

The defect results from compression of the anterior-posterior aspect of the globe, which stretches the anterior segment structures and leads to the separation of the iris root from the ciliary body.(2)

Frequently, anterior segment hemorrhage ensues, and the iridodialysis may not be recognized until the hyphema has cleared. (3)

Surgical intervention in iridodialysis is indicated when the tear is a large one over 3.5 mm , the iris obstructs the pupil and the size of the rent in the iris root is likely to cause uniocular diplopia .(4)

A small iridodialysis with no visual disturbance attributable to it is left alone. The purpose of surgical intervention is to induce a peripheral synechiae at the filtration angle . Malcolm mc Cannel (1976) has ascribed an ingenious of effecter method of surgical repair . the beauty of the method is that the sutures are placed before any fluids lost from the anterior chamber (4) .

In this report we describe the repair of different degree of traumatic iridodialysis using open chamber technique with fornix based conj flap

Patients and methods :

11 eyes of 11 patients with different degrees of traumatic iridodialysis ranging from 2 hours to 6 hours were included in this study . all the eyes were closed globe injuries , 5 of them associated with hyphema. The age range between 5 and 62 years . all the operations repair done under general anesthesia except one (65 years) done under local anesthesia using 2% xylocaine with adrenaline given peribulbarly (2.5 ml) with van linc (2.5 ml) . the operations done after subsidence of hyphema if present .

Surgical procedure :

The procedure described here is one which was used with largest iridodialysis included in the study and also applied in smaller degrees in other cases . In this case a 65 years old female was referred to al sadder medical city on 20-1-20011 with one month history of blunt trauma to the right eye .Ophthalmic examination of the right eye revealed the following findings :Visual acuity was 2/60 and intraocular pressure was 18 mmhg . Slitlamp biomicroscopy showed clear cornea ,formed anterior chamber and a large (6 clock ours) extending from 12 o'clock t 6 oclock temporally with superonasally displaced pupil . lens was clear with temporal zonular dehiscence .(Figure no.1)

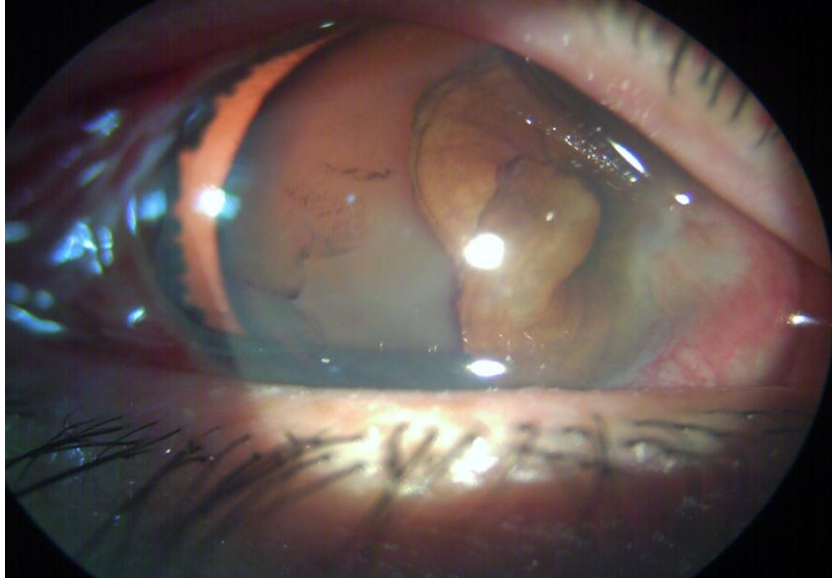


Figure no.1

A temporal lateral canthus based conjunctival peritomy was fashioned for better approach to iridodialysis . 3 partial thickness canthus based temporal sclerotomies done . .(Figure no.2)

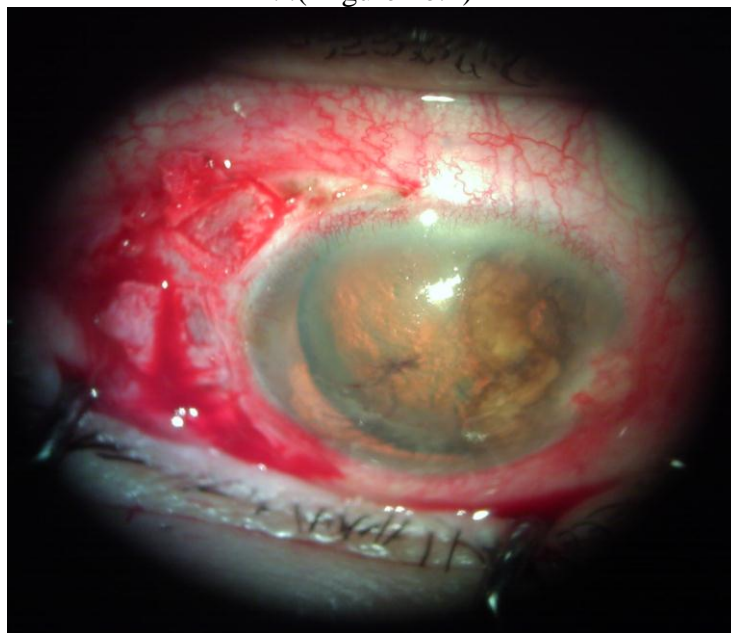


Figure no.2

a limbal self sealing wound done was made through each sclerotomy in succession .Through the opening of each wound viscoelastic material was injected into anterior chamber and the facing iris root was withdrawn to the wound using an atraumatic forceps . Double armed non traumatic 10-0 polypropylene suture was used where the needles first passed through the iris root and then through the sclera from inside out .the suture was drawn to approximate the iris root to the base, the suture was tied and the knot put within the sclerotomy . .(Figure no.3,4,5,6)

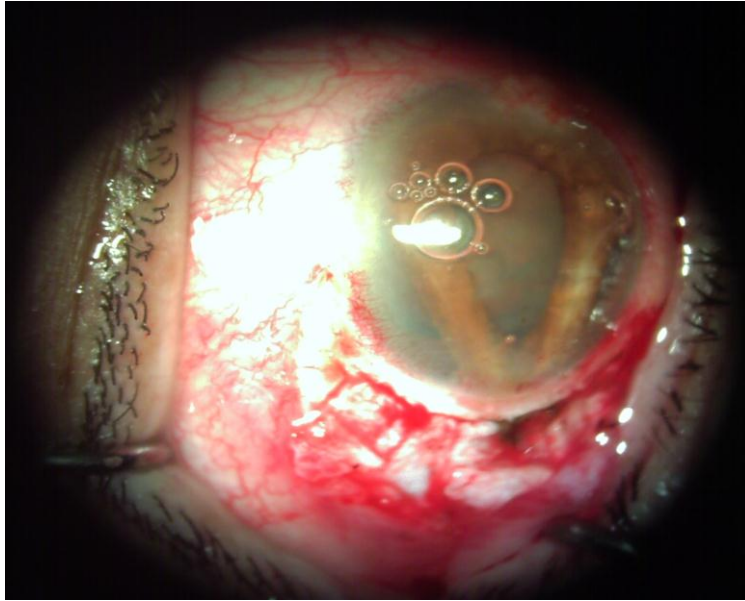


Figure no.3

Then each scleral flap was sutured with 80VS .Helon washed out using simco irrigation aspiration cannula and anterior chamber was reformed with air . lastly conj flap sutured with 80VS .

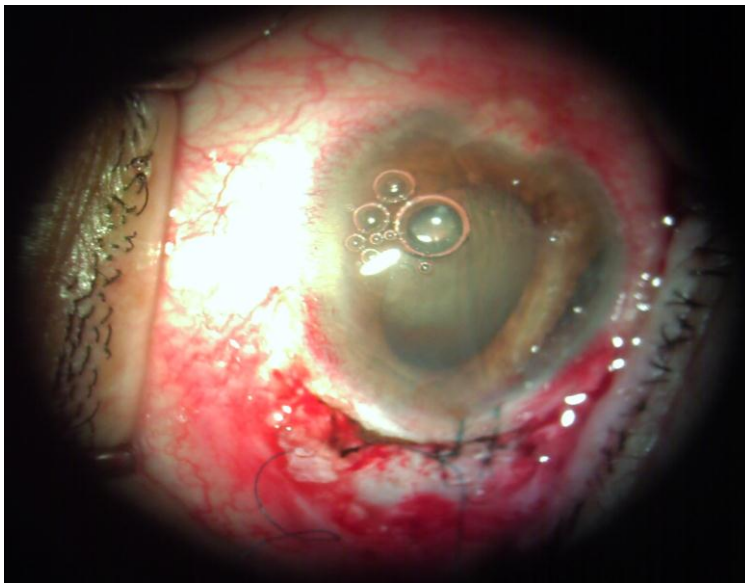


Figure no.4

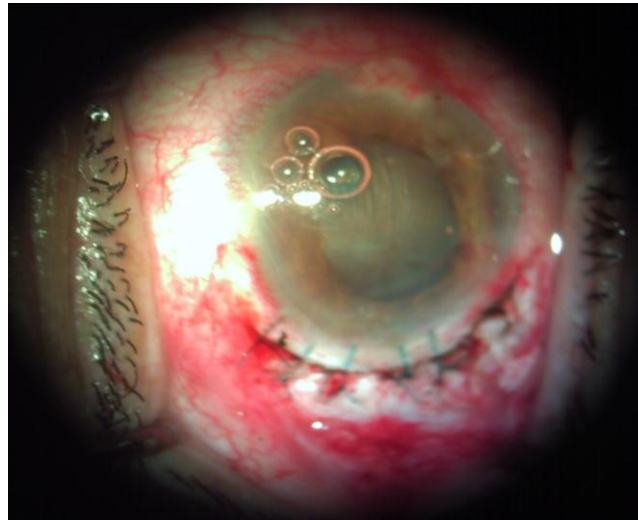


Figure no.5

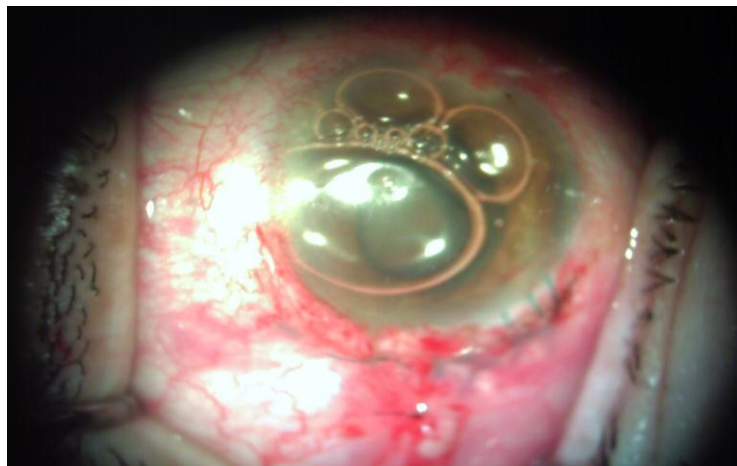


Figure no.6

Subconjunctival injection of garamicin and dexamethasone given. Postperatively, patient treated with topical antibiotic and steroid 2 hourly for 1 weak and 4 hourly for 4 weeks together with atropine 1% three times daily.

Figure no.7 shows the eye 1 weak after operation

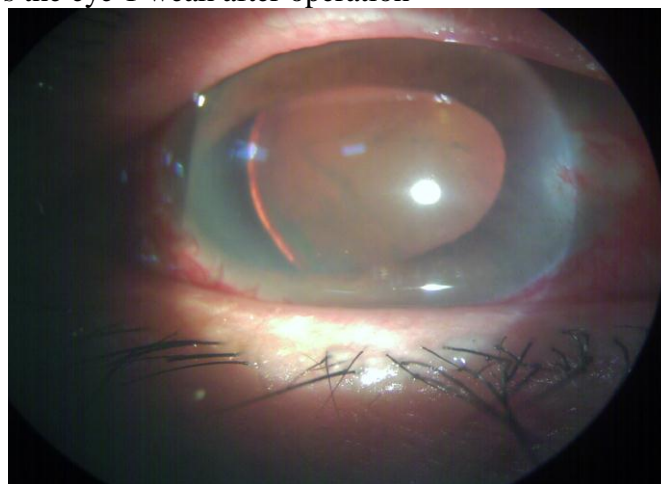


Figure no.7

Discussion

The techniques described to repair iridodialysis can be classified under 2 groups; open chamber techniques and closed chamber techniques. Open chamber techniques access the iridodialysis site through a limbal self-sealing incision or a scleral tunnel incision .(2)

In this study open chamber technique is used with fornix based scleral flap .Scleral flap was done in this technique to ensure the best approximation of the iris to its root and stable suture placement .

However, scleral flap preparation is time consuming and hard to perfect, and have problems, such as erosion and infection (5,6).

Although still many ophthalmic surgeons are reluctant to repair iridodialysis . We present this study to ensure the even large iridodialysis can be repaired even under local anesthesia with good result . Even if there is differences in the techniques between the surgeon .

Şengül ÖZDEK described a technique of iridodialysis in which the knot is left in the anterior chamber to avoid suture related complications (7)

The technique described in this study can be done in the usual standards of operation theatre in Iraq and can be mastered by an ophthalmologist without requiring high level of training .

It is a simple and easy to understand method, which may be performed by any ophthalmologist and needs no special dexterity. It can be performed with routine surgical instruments and does not necessitate expensive instruments. It also appears to be a safe method because it did not cause any significant complications during the operation or in the postoperative period.

Reference:

- 1- Jack J. Kanski: Clinical Ophthalmology. 6th ed. 2007; P 855.
- 2- Paton D , Craig J Management of ididodialysis .Ophthalmic Surg1973 4(1) : 38-39
- 3- American Academy of Ophthalmology: External Disease and Cornea .2011-2012 ; P 364
- 4- M.J.Roper-Hall : Stallard`s Eye Surgery .7th ed.1989; P 273
- 5- Solomon K , Gussler JR , Gussler C, Van Meter WS.Incidence and management of complications of transsclerally sutured posterior chamber lenses . J Cataract Refractive Surg 1993;19:488-493
- 6- Heilskov Ti Brian CJ ,Karl RO, Blankenship GW .Late endophthalmitis after transscleral fixation of a posterior chamber intraocular lens .Arch Ophthalmol 1989;107:1427
- 7- Mehmet C ÖZMEN . A Simple Surgical Technique for Repair of Iridodialysis . Turk J Med Sci 2009; 39 (2): 317-319